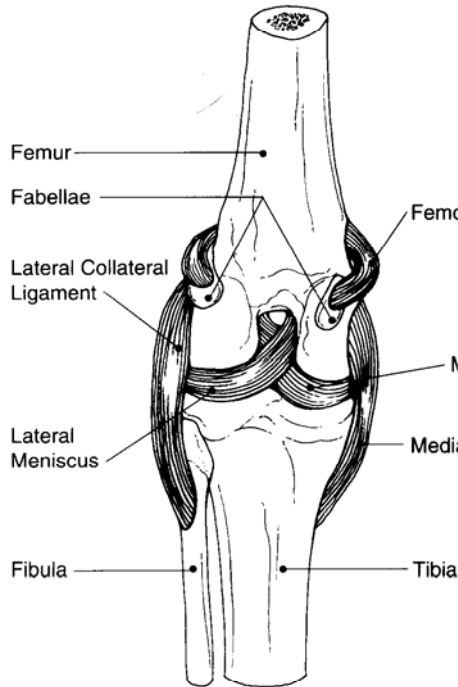
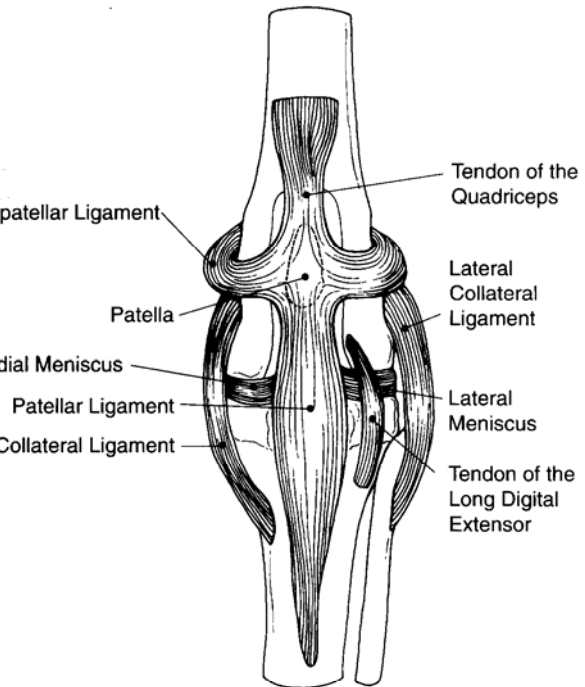


CANINE STIFLE (KNEE) MODEL

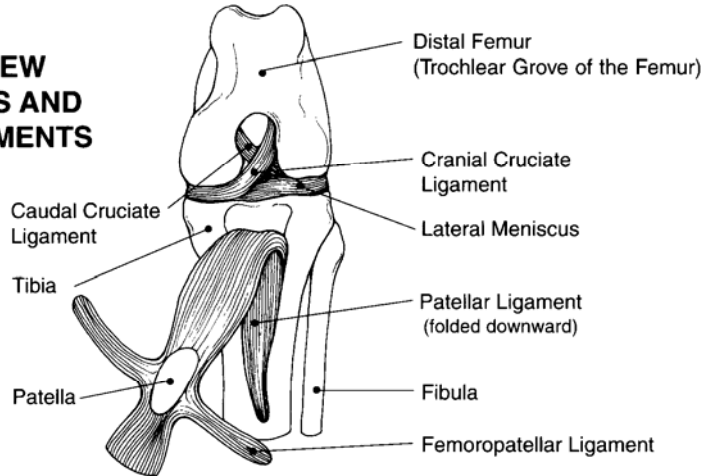
POSTERIOR VIEW

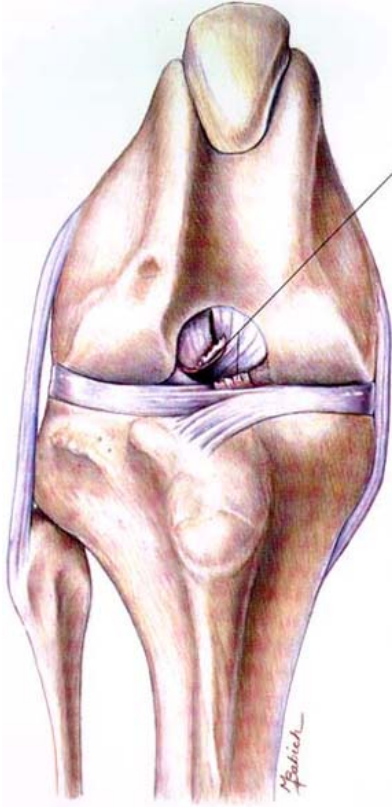


ANTERIOR VIEW



**ANTERIOR VIEW
WITH MENISCUS AND
CRUCIATE LIGAMENTS
EXPOSED**





Ends of the ruptured cranial cruciate ligament

Ruptured Cranial Cruciate Ligament

Diagnostic Plan

History
Physical examination
Palpation of the knee
X-rays of the knee

Therapeutic Plan

Enforced rest
Analgesics
Surgery

Dietary Plan

Postsurgically, a diet adequate for tissue repair
If obesity is a complicating factor, restrict caloric intake so the patient reaches and maintains an ideal body weight